

PATIENT

Bandit Smith

SPECIES

Canine

BREED

Chihuahua

SEX

Male Neutered

AGE

10 years

WEIGHT

12.1lbs

INTERPRETED BY

Maggie Machen Lamy,
DVM, DACVIM
(Cardiology)

IMAGING PERFORMED BY

Patti Mayfield, DVM

HOSPITAL NAME

Broken Top Veterinary
Clinic

REFERRING VET

Dr. McSwain

INVOICE

47645

DATE

4/22/26

PRESENTING CLINICAL SIGNS

History: Grade 3/6 heart murmur. Elevated BNP: 1729.
On Pimobendan 2.5mg ½ tab PO BID and Enalapril 5mg ½ PO BID. Sedated with Torb.

ECHOCARDIOGRAM FINDINGS

2D, m-mode, color flow and doppler imaging is available. Diffuse thickening of mitral valve leaflets with prolapse into the left atrial lumen. Severe eccentric mitral regurgitation with severe left atrial dilation. LV dilation with hyperdynamic myocardial function. The tricuspid valve appears mildly thickened with mild tricuspid regurgitation. TR velocity is mildly elevated. Right heart is mildly dilated. The pulmonic and aortic valves are normal in morphology and mobility. Normal pulmonic and aortic outflow velocities. No aortic or pulmonic insufficiency. No pericardial or pleural effusion noted. No obvious cardiac tumors observed.

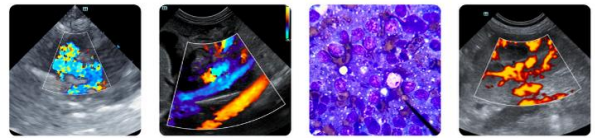
CARDIAC CHART

CANINE CARDIAC PARAMETERS	MR VMAX (m/s)	TR VMAX (m/s)	LA/AO (Boon method)	LA/AO (Heart Base; Swe)	FS (%)	EF (%)	EPSS (cm)
NORMAL PARAMETER	4.5-5.5	<2.7	1.3	<1.6	28-40	40-100	<0.6
PATIENT	6.1	3.0	1.8	2.1	52	90	NM
CANINE CARDIAC PARAMETERS	HR (BPM)	AV VMAX (m/s)	PV MAX (m/s)	BODY WEIGHT (kg)	LA 2D short axis Base view (cm)	LVIDd Avg; 2D and m-mode short axis (cm)	LVIDs Avg; 2D and m-mode short axis (cm)
NORMAL PARAMETER	50-100	0.7-1.7	0.7-1.6	BELOW	BELOW	BELOW	BELOW
PATIENT	NM	1.5	1.1	5.5	2.2	3.0	1.5
*Normal chamber parameters expressed as a mean value (SD)				3	1.27 (5.3)	2.46 (2.46)	1.36 (5.5)
BODY WEIGHT DEPENDENT PARAMETERS				5	1.40 (4.5)	2.74 (5.2)	1.60 (4.7)
<i>*Note: All measurements based upon multi-modal images and methods. An average value is reported.</i>				10	1.50 (3.8)	3.27 (3.5)	2.06 (3.1)
				15	1.83 (2.0)	3.71 (2.4)	2.43 (2.1)
				20	2.02 (1.9)	4.14 (2.2)	2.80 (2.0)
				25	2.18 (2.4)	4.48 (2.9)	3.10 (2.5)
				30	2.33 (3.3)	4.83 (3.9)	3.39 (3.4)
				35	2.48 (4.3)	5.17 (5.0)	3.69 (4.5)
				40	2.62 (5.2)	5.48 (6.1)	3.96 (5.4)
				50	2.88 (7.1)	6.07 (8.3)	4.46 (7.4)

INTERPRETATION OF THE FINDINGS & FURTHER RECOMMENDATIONS

The murmur is due to chronic degenerative valve disease causing severe mitral and mild tricuspid regurgitation. Significant left atrial and ventricular enlargement indicate the risk for spontaneous congestive heart failure is elevated. Mild pulmonary hypertension is noted, which is likely secondary to a reported cough and elevated LA pressure. No obvious additional issues are noted.

A cough in this patient with severe heart disease is likely multi-factorial in origin, including mainstem bronchi compression and/or potentially some degree of upper or lower airway



PATIENT

Bandit Smith

SPECIES

Canine

BREED

Chihuahua

SEX

Male Neutered

AGE

10 years

WEIGHT

12.1lbs

INTERPRETED BY

Maggie Machen Lamy,
DVM, DACVIM
(Cardiology)

IMAGING PERFORMED BY

Patti Mayfield, DVM

HOSPITAL NAME

Broken Top Veterinary
Clinic

REFERRING VET

Dr. McSwain

INVOICE

47645

DATE

4/22/26

disease. Early CHF/pulmonary edema should also be considered; however, this is less likely based upon a reported cough in the absence of labored breathing. CXR should be obtained to rule out early CHF. Recommend institute cardiac supportive medications including a weak diuretic (spironolactone) for potential survival benefit and advise close monitoring at home for need for Lasix therapy. Cough suppression (up to q4-6 hours) may also be helpful for any component of a mechanical cough. **Monitoring of sleeping breathing rates is recommended as the best way to screen for CHF at home.**

Omega fatty acid supplementation and mild salt restriction may also be of some long-term benefit. Monitor for development of a worsening cough, labored breathing, exercise intolerance or collapse episodes. Long term prognosis is guarded to poor with stage (late) B2 disease, with risk for CHF in the near future. Once diagnosed, the average survival time for canine patients is 8-9 months on medications; however, most are able to maintain a good quality of life for that period. Patient will always be at risk for progression to CHF, development of arrhythmias/LA tear, syncope and/or sudden death in the future.

Elective anesthesia is not advised, as there is high risk for complication.

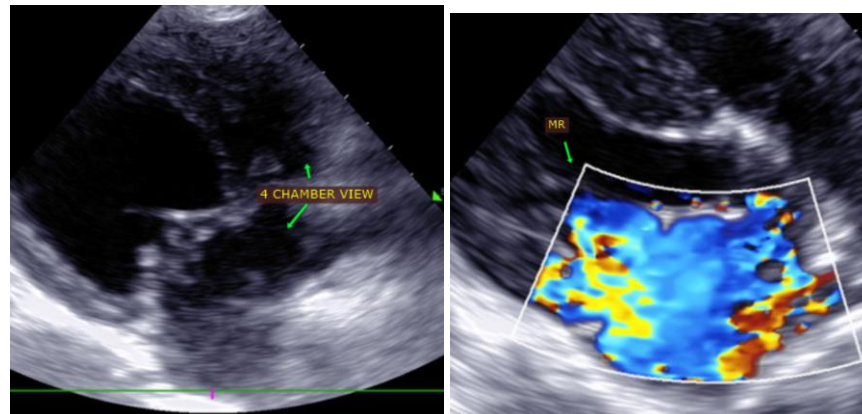
PLAN

Baseline BP and CXR recommended. Continue Pimobendan 0.3mg/kg PO q12h. Institute Spironolactone 1-2mg/kg PO q12h. Continue Enalapril 0.5mg/kg PO q12h. Consider hydrocodone with homatropine for QOL (0.2-0.4mg/kg PO up to q4-6 hours PRN for cough; available in 5/1.5mg tabs and 5mg/5ml liquid suspension).

A renal panel and BP are recommended in 1-2 weeks, then every 3-4 months lifelong to ensure tolerance of medications.

A recheck echocardiogram is recommended in 6 months to screen for progression, sooner if clinical signs arise in the interim.

IMAGES





PATIENT

Bandit Smith

SPECIES

Canine

BREED

Chihuahua

SEX

Male Neutered

AGE

10 years

WEIGHT

12.1lbs

INTERPRETED BY

Maggie Machen Lamy,
DVM, DACVIM
(Cardiology)

IMAGING PERFORMED BY

Patti Mayfield, DVM

HOSPITAL NAME

Broken Top Veterinary
Clinic

REFERRING VET

Dr. McSwain

INVOICE

47645

DATE

4/22/26

The information and recommendations provided are based on the images presented by the referring veterinarian. No evaluation can be communicated regarding pathology that was not visible in the image/video clips provided.

Thank you for this referral. This report was generated using transcription software, and minor dictation errors may be present. If the clinical or image interpretation does not parallel your findings or if I can be of any further assistance, please contact me.

Maggie Machen Lamy, DVM
Diplomate of the American College of Veterinary Internal Medicine (Cardiology)
info@sonopath.com